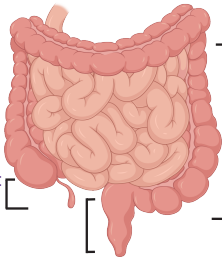


Could it be Eosinophilic GI Disease?

During my colonoscopy please consider:

- History of bowel symptoms
+/- atopy
- Can appear normal or inflamed;
biopsy both areas
- Ask the pathologist to provide
eosinophil counts and assess
inflammation

Terminal Ileum:
2-4 biopsies



Ascending,
Transverse,
Descending
Colon: 4
biopsies at
each site

Sigmoid/Rectum:
4 biopsies

Learn more:



Consortium of Eosinophilic
Gastrointestinal
Disease Researchers

Images created in BioRender