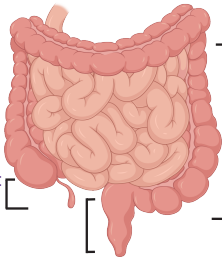


# Could it be Eosinophilic GI Disease?

## During my colonoscopy please consider:

- My history of bowel symptoms +/- atopy
- Can appear normal or inflamed; biopsy both areas
- Ask the pathologist to provide eosinophil counts and assess inflammation

Terminal Ileum:  
2-4 biopsies



Ascending,  
Transverse,  
Descending  
Colon: 4  
biopsies at  
each site

Sigmoid/Rectum:  
4 biopsies

Learn more:



Consortium of Eosinophilic  
Gastrointestinal  
Disease Researchers

Images created in BioRender