

Could it be Eosinophilic GI Disease? During my endoscopy please consider:

- My history of bowel symptoms +/- atopy
- Can appear normal or inflamed; biopsy both areas
- Ask the pathologist to provide eosinophil counts and assess inflammation

Esophagus
Proximal &
Distal: 2-3
biopsies at
each site

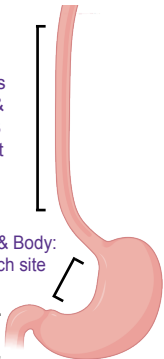
Stomach Antrum & Body:
4 biopsies at each site

Duodenum Bulb &
2nd Portion:
2-4 biopsies at each site

Learn more:



Consortium of Eosinophilic
Gastrointestinal
Disease Researchers



Images created in BioRender