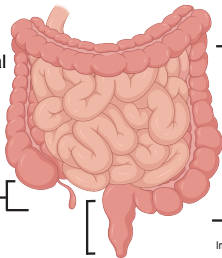


## Could it be Eosinophilic GI Disease?

### During my colonoscopy please consider:

- My history of bowel symptoms  
+/- atopy
- Biopsy even if it looks normal  
(It can be patchy)
- Ask the pathologist to provide  
eosinophil counts and  
assess inflammation



Terminal Ileum:  
2-4 biopsies

Ascending,  
Transverse,  
Descending  
Colon:  
4 biopsies  
at each site

Sigmoid/Rectum:  
4 biopsies

Learn more at:



Consortium of Eosinophilic  
Gastrointestinal  
Disease Researchers

Images created in Biorender